

## RESEARCH ARTICLE

## THE STUDY OF THE EFFECTS OF PREDNISOLONE ON THE CEREBRAL CORTEX OF WISTAR RATS

Buraimoh A.A. 1\*, Samuel, S.D.1 and Ojo, S.A.2

1. Department of Human Anatomy, Faculty of Medicine, Ahmadu Bello University, Zaria, Nigeria.

2. Department of Veterinary Anatomy, Faculty of Veterinary Medicine, Ahmadu Bello University, Zaria, Nigeria.



Date Received:

27-Mar-2014

Date of Accepted:

13-Apr-2014

Date Published:

21-Apr-2014

**Abstract:**

Prednisolone is an oral, synthetic (man-made) corticosteroid used for suppressing the immune system and inflammation. It belongs to the general class of medicines called „steroids“ which are used to treat a number of conditions; for example inflammation, asthma, arthritis and allergic reactions. Steroids are used with other medicines to prevent the body from rejecting transplanted organ. The purpose of this study was to evaluate the possible effects that Prednisolone could have on the cerebral cortex of wistar rats. Twenty (20) wistar rats were used for this experiment; they were divided into four groups with each group consisting of five Wistar rats. Group I was the control, while groups II, III, and IV were given 5mg/kg, 15mg/kg and 20mg/kg of Prednisolone respectively for a period of fourteen (14) days via oral intubations. The brain tissues were fixed, processed and stained in haematoxylin and eosin; and the slides were viewed under the light microscope fitted with a digital camera and laptop. Our results showed neuronal degeneration of the cerebral cortex of the Prednisolone treated groups when compared with the control. Based on our observations, we therefore conclude that Prednisolone administration resulted into neurodegeneration of the cerebral cortex of Wistar rats.

**Keywords:** Prednisolone, Effects, cerebral cortex, corticosteroid, neurodegeneration and wistar rats

**Introduction**

Prednisolone is a synthetic glucocorticoid, a derivative of cortisol, which is used to treat a variety of inflammatory and auto-immune conditions. It is the active metabolite of the drug prednisone and is used especially in patients with hepatic failure, as these individuals are unable to metabolise prednisone into Prednisolone [1].

It is a corticosteroid drug with predominant glucocorticoid and low mineralocorticoid activity, making it useful for the treatment of a wide range of inflammatory and auto-immune conditions [2], such as asthma, [3]. It is also used for the treatment of uveitis, pyoderma gangrenosum, rheumatoid arthritis, ulcerative colitis, pericarditis, temporal arteritis, Crohn's disease, Bell's palsy, multiple sclerosis [4]. It is also employed for the management of cluster headaches, vasculitis, acute lymphoblastic leukemia and autoimmune hepatitis [5]; systemic lupus erythematosus, Kawasaki disease and dermatomyositis [6].

Corticosteroids inhibit the inflammatory response to a variety of inciting agents and it is presumed, delay or slow healing. They inhibit the edema, fibrin deposition, capillary dilation, leukocyte migration, capillary proliferation, fibroblast proliferation, deposition of collagen, and scar formation with inflammation.

The cerebral cortex is the biggest part of the brain. This large and complicated neural circuit is involved in most of the brain's highest functions, such as memory, language and sight. In man and higher animals, modifications of behaviour are due to cortical activity [7].

The cerebrum consists of two cerebral hemispheres that are partially connected with each other. A coronal section through the cerebral hemisphere shows each hemisphere has three borders: superiomedial, inferolateral and inferiomedial:

These borders divide the surface of the hemisphere into three Large surfaces: superolateral, medial and inferior; the inferior surface is further divided into anterior orbital part and posterior tentorial part. Each cerebral hemisphere is divided into four major subdivisions or lobes. These are: The frontal lobe- it lies anterior to the central sulcus, and above the posterior ramus of the lateral sulcus [8]. The parietal lobe: lies behind the central sulcus. It is bounded below by the posterior ramus of the lateral sulcus and by the second imaginary line; and behind the upper part of the first imaginary line. The occipital lobe: is the area lying behind the first imaginary line. The temporal lobe: lies below the posterior ramus of the lateral sulcus and second imaginary line. It is separated from the occipital lobe by the lower part of first imaginary line[8].

The two hemispheres of man are not symmetrical in their control of several functions. Speech, reading and writing for example, are vested in the left hemisphere, whereas the analysis of music is in the right (or right handed persons). These cortical areas account for most of the cortex of lower mammals (Marsupials and Insectivores), but for only one-quarter of the cortex of man [9].

The cerebral cortex develops from the most anterior part of the neural plate, a specialized part of the embryonic ectoderm. The neural plate folds and closes to form the neural tube. From the cavity inside the neural tube develops the ventricular system, and, from the epithelial cells of its walls, the neurons and glia of the nervous system. The most anterior (frontal) part of the neural tube, the telencephalon, gives rise to the cerebral hemispheres and cortex [10].

Cortical neurons are generated within the ventricular zone, next to the ventricles. At first, this zone contains "progenitor" cells, which divide to produce glial and neuronal cells [11]. The glial fibers produced in the first divisions of the progenitor cells are radially oriented, spanning the thickness of the cortex from the ventricular zone to the outer, pial surface, and provide scaffolding for the migration of neurons outwards from the ventricular zone.

The first divisions of the progenitor cells are symmetric, which duplicates the total number of progenitor cells at each mitotic cycle. Then, some progenitor cells begin to divide asymmetrically, producing one postmitotic cell that migrates along the radial glial fibers, leaving the ventricular zone, and one progenitor cell, which continues to divide until the end of development, when it differentiates into a glial cell or an ependymal cell.

The migrating daughter cells become the pyramidal neurons of the cerebral cortex [10]. The aim of this study was to evaluate the possible effects that Prednisolone could have on the cerebral cortex of Wistar rats.

## MATERIALS AND METHODS:

### Materials:

The materials used include the following: twenty Wistar rats, Syringes, needles, distil water, Steel cages, pelletized feeds, weighing balance, Prednisolone tablets, tissue processing reagents, Bouins fluid, Cotton wool, cover slip, slides, Chloroform and tap water.

### Experimental Animals:

Twenty (20) wistar rats were used for this experiment. They were procured from the faculty of pharmaceutical sciences' animal house, Ahmadu Bello University, Zaria, Nigeria. The Wistar rats were kept in the Department of Human Anatomy's Animal House, Ahmadu Bello University Zaria, Nigeria for two weeks before the commencement of administration; this was to allow the animals acclimatized to the new environment. The Wistar rats were fed with pelletized grower feeds and allowed to drink water freely at will throughout the experiment.

### Experimental Design:

The Wistar rats were divided into four groups with each group consisting of five Wistar rats. Group I was the control that received distil water only, group II received 5mg/kg, group III received 15mg/kg and group IV received 20mg/kg of Prednisolone per body weight for a period of fourteen (14) days via oral intubations. After the expiration of fourteen days of administration, the brain tissues were dissected and fixed in Bouin's fluid. The tissue were then transferred into the automatic tissue processor where they undergo dehydration in each of the ascending grades of alcohol, 70%, 80%, 90%, and absolute alcohol for two changes each. After which the tissue were cleared in chloroform and embedded in paraffin wax. Serial sections of five microns thick were obtained from a rotatory microtome. The deparaffinized sections were routinely stained with haematoxyline and eosin method "H&E" [12]; and the stained slides were viewed under the light microscope fitted with a digital camera and laptop.

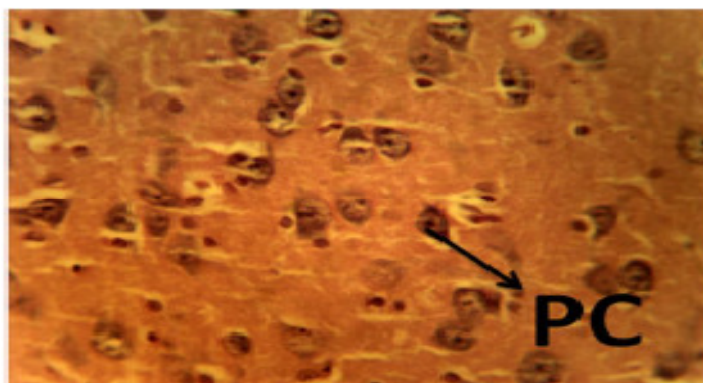


Plate I: Photomicrograph of the cerebral cortex of the group I, control, showing normal histology of cells. The pyramidal cells (PC) appeared distinct. H&E, X250.

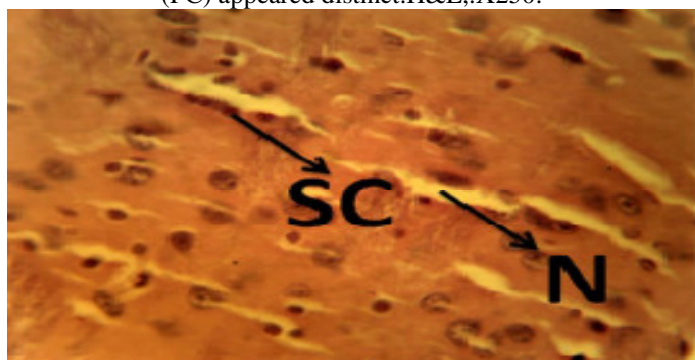


Plate II: Photomicrograph of the cerebral cortex of the group II, showing neurodegenerations (N) and areas of satellite cells affected. H&E, X250.

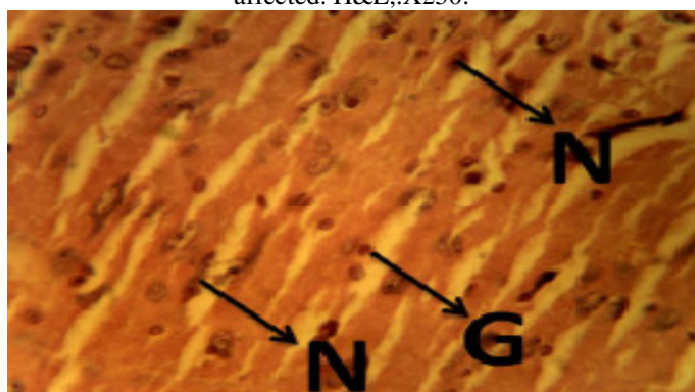


Plate III: Photomicrograph of the cerebral cortex of the group III, showing neurodegenerations (N) and Gliosis. H&E, X250.

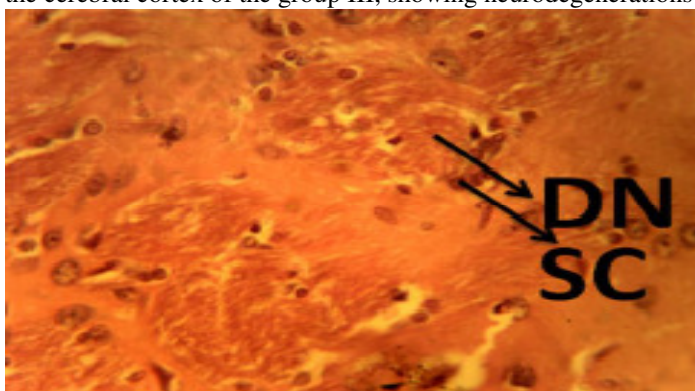


Plate IV: Photomicrograph of the cerebral cortex of the group IV showing localized areas of degenerating neurons (DN) and also areas of satellite cells affected. H&E, X250.

The cerebral cortex is the key structures of memory formation. It also integrates higher mental functions, general movement, visceral functions, and behavioral reactions [13, 14]. Prednisolone irreversibly binds with glucocorticoid receptors (GR) alpha and beta for which they have a high affinity. AlphaGR and BetaGR are found in virtually all tissues with variable numbers between 3000 and 10000 per cell, depending on the tissue involved. Prednisolone can activate and influence biochemical behaviour of most cells. The steroid/receptor complexes dimerise and interact with cellular DNA in the nucleus, binding to steroid-response elements and modifying gene transcription. They induce synthesis of some proteins, and inhibit synthesis of others. [15, 16]. In this present study, the effects of Prednisolone was evaluated in Wistar rats. The cerebral cortex of group I, the control, that received distil water only showed normal cytoarchitector of the histology of the cerebral cortex, with distinct appearance of the pyramidal cells (Plate I). The cerebral cortex of Wistar rats in group II that received 5mg/kg of Prednisolone showed slight degeneration of the pyramidal cells and the glial cells were looking intact (See Plate II). The photomicrograph of group III Wistar rats that received 15mg/kg of Prednisolone showed nonspecific reactive change of glial cells in response to damage (gliosis) possible caused by prednisolone administration (Plate III).

#### REFERENCES:

1. Davis, M., Williams, R. & Chakraborty, J. (1978). "Prednisone or prednisolone for the treatment of chronic active hepatitis? A comparison of plasma availability". *British Journal of Clinical Pharmacology* 5 (6): 501-5. PMC 1429358 PMID 656293.
2. Czock, D., Keller, F., Rasche, F.M. & Häussler, U. (2005). Pharmacokinetics and pharmacodynamics of systemically administered glucocorticoids. *Clin Pharmacokinet.* 2005;44(1):61-98. Review. PMID 15634032.
3. Fiel, S.B. & Vincken, W. (2006). Systemic corticosteroid therapy for acute asthma exacerbations. *J Asthma.* 2006 Jun-Jul;43(5):321-31. Review. PMID 16801135.
4. Thrower, B.W. (2009). Relapse management in multiple sclerosis. *Neurologist.* 2009 Jan; 15(1):1-5. Review. PMID 19131851.
5. Lambrou, G.I., Vlahopoulos, S., Papathanasiou, C., Papanikolaou, M., Karpusas, M., Zoumakis, E. & Tzortzatou-Stathopoulou, F. (2009). Prednisolone exerts late mitogenic and biphasic effects on resistant acute lymphoblastic leukemia cells: Relation to early gene expression. *Leuk Res.* 2009 May 16. [Epub ahead of print] PMID 19450877.

The histology of the cerebral cortex for group IV Wistar rats that received 20mg/kg of prednisolone revealed localized areas of neurodegenerations which was very severe (Plate IV) when compared with the group I that received only distil water (Plate I). Our study revealed that, although Prednisolone is useful in the treatment of wide range of inflammatory and auto-immune conditions [2], it had a negative effects on the cerebral cortex of Wistar rats as evident in the neurodegenerations of the cerebral cortex of Wistar rats treated with prednisolone (Plates II, III and IV) when compared with the control (group I) that showed normal histology of the cells of the cerebral cortex (Plate I).

#### CONCLUSION:

Based on our observations, we therefore conclude that prednisolone, although, an anti-inflammatory drug, had neurodegenerative effects on the cerebral cortex of Wistar rats and hence could affect memory formation and integration of higher mental functions, general movement, visceral functions, and behavioral reactions.

#### ACKNOWLEDGMENT:

The authors wish to acknowledge the immense support and contribution given by the Vice Chancellor of Ahmadu Bello University, Zaria, Nigeria towards the successful completion of this research work.

6. Miura, M., Tamame, T., Naganuma, T., Chinen, S., Matsuoka, M. & Ohki, H. (2011). Steroid pulse therapy for Kawasaki disease unresponsive to additional immunoglobulin therapy. *Paediatrics & Child Health.* 16(8), 479-84. PMID 23024586.
7. Pavlov, I.P. (1927). *Conditional Reflexes.* Oxford University Press, London.
8. Inderbir, S. (2002). *Human Neuroanatomy* : 6th edition; Jaypee Medical publishers Ltd pg: 67-69.
9. Mettler, F.A. (1935). Coticifugal fiber connections of the cortex of *Macaca mulata*. *Journal of comparative neurology.* 63: 23-47.
10. Creutzfeldt, O. (1995). *Cortex cerebri.* Springer-verlag.
11. Rakic, P. (1988). "Specification of cerebral cortical areas". *Science* 241, (4862): 170-176. doi:10.1126/science.3291116. PMID 3291116. <http://www.sciencemag.org/cgi/content/abstract/241/4862/170>.
12. Drury R.A.B., Wallington, E.A. & Cameron, R. (1967). *Carleton's Histological Technique*: 4th ed., Oxford University Press NY, USA, 279-280.
13. Brodal, S. (1977). *The Central Nervous system: Structure and Function.* Oxford University Press.
14. Cauller, L. (1995). Layer I of primary sensory neocortex: where top-down converges upon bottom-up. *Behav Brain Res.*, 71(1-2):163-70. PMID 874718

15. Australian Medicines Handbook (2010). Prednisolone. Adelaide: Australian Medicines handbook Pty Ltd.; 497, 598.
16. Rang, H.P., Dale, M.M., Ritter, J.M. & Moore, P.K. (2003). The pituitary and the adrenal Cortex. Hunter I, editor. Pharmacology. 5th ed. London: Churchill Livingstone; 2003. 413, 415.